

ORIGINAL ARTICLE

Cast application of four weeks' duration significantly affects hair length, diameter and density

Piyanuch Chairerg¹, Saran Tantavisut², Aree Tanavalee², Wirach Tuangjaruwina¹, Ratchathorn Panchaprateep¹ & Pravit Asawanonda¹

¹Department of Medicine, Division of Dermatology, Faculty of Medicine, King Chulalongkorn Memorial Hospital, Chulalongkorn University, Bangkok, Thailand and ²Department of Orthopedics, Faculty of Medicine, Chulalongkorn University, Bangkok, Thailand

Background: Localized hypertrichosis following cast application has been recorded, yet no studies characterized these changes systematically. **Objective:** To evaluate changes of hair length, diameter and density on the legs in patients after cast application. **Materials and methods:** Patients with leg injuries and cast application of at least 4 weeks' duration were included in the study. Immediately after cast removal, hair sampling was taken from both legs; cast and control sides. Hair length and diameter were measured by Olympus microscope software. Patients were also analyzed for global changes by three blinded dermatologists. **Results:** Fourteen patients, seven of whom were male, were included in this study. On the cast side, both hair length and diameter were significantly greater than the control side ($p < 0.001$). Subjective evaluations by three blinded dermatologists agreed well with objective measurements and also demonstrated an increase in overall density. Degrees of hair changes did not correlate with the distance from injury sites. **Conclusion:** Cast application of at least 4 weeks' duration significantly stimulates hair growth in a diffuse pattern. This could possibly lead to novel therapeutic approaches for different types of alopecias.

Key words: hair, hypertrichosis, cast, fracture

Introduction

Localized hypertrichosis from various physical insults, such as ultraviolet radiation (1), friction and chronic pressure has been documented (2). There are a number of reports illustrating patients with hypertrichosis secondary to cast application which gradually resolved with time after cast removal (2–6). Although most was seen in patients with bone fracture, hypertrichosis after cast application, both plaster of Paris and fiberglass for soft tissue injuries have been recorded (2,7). Interestingly, Bergen (6) and Harper (8) reported that hair underneath the casts was thicker and longer than the contralateral side in a diffuse pattern. The authors sought to evaluate the characteristics of hair changes after cast application compared with the control side.

Methods

Study design

To evaluate changes of hair growth on the legs after cast application, the authors initiated a single-center, cross-sectional study

involving orthopedics patients at King Chulalongkorn Memorial Hospital. Patients with cast application who met the study criteria were enrolled. The study was approved by the ethics committee of Faculty of Medicine, Chulalongkorn University. Written informed consent was obtained from each patient before starting the study.

Patient enrollment

The authors included orthopedics patients of all ages who had cast application on one leg for at least 4 weeks. Patients with chronic skin inflammation at the site prior to cast application, history of hair removal (by shaving, laser, wax or depilatory agents), history of topical medication which may affect hair growth, that is minoxidil, anthralin, steroid, dinitrochlorobenzene as well as those who had casts applied to both legs or those with minimal terminal hair were excluded.

Data collection

All data were collected on the day of cast removal. Reviews of medical history and general demographic data were carried out from both chart reviews and patient interviews. On the very same day, standardized digital photography (Canon PowerShot G12, Ohta-ku, Tokyo, Japan) was taken and hair sampling obtained. The target site of study was an area measuring 3×3 cm, 15 cm distal to the tibial tubercle along bone axis. After marking the corresponding sites on both legs, all hairs within this square were collected by shaving close to the skin then placed in plastic boxes with blind coding 1 or 2. Five hairs from each box were randomly sampled and processed on to glass slides (Figure 1). Hair length and hair diameter were measured using Olympus Microscope Software DP2-BSW (Olympus America Inc., Center Valley, PA, USA) and recorded in millimeters (mm) and micrometers (μm), respectively. The length was measured in its entirety and diameter at the proximal cut ends to represent the newly formed hair (Figure 2). Intraclass correlation coefficients (ICC) from repeated measurements were at 0.98 and 1.00 for hair length and diameter, respectively. As a result, single measurement for each hair was performed.

The overall appearance was assessed by comparing digital photographs of the two legs. Being blinded to the history of cast application, three board-certified dermatologists separately rated whether the hair on one leg was longer, broader and denser than the contralateral side. The scores for these changes ranged




Figure 1. Hairs fixed on glass slides for length measurement.

from -3: remarkably less, -2 moderately less, -1 minimally less, 0 no change, +1 minimally greater, +2 moderately greater and +3 remarkably greater.

Statistical analysis

Sample size was calculated based on a smaller pilot study. The demographic data were analyzed and demonstrated as ratios, percentages, means and standard deviations. Comparison of hair length and diameter between cast and control sides was analyzed using paired t-test. The p -value < 0.05 was considered statistically significant. The subjective assessment scores for hair changes were shown as ratios and percentages.

Results

A total of 14 patients were included as shown in Table I. Enrollees consisted of seven male and seven female with ages ranging from 12 to 82 years. All patients had plaster of Paris applied. Reasons for cast application were bone fracture (78.57%) and soft tissue injuries (21.43%). Duration of cast application varied from 4 to 16 weeks.

The mean length of hairs from legs with cast application was 23.30 ± 4.94 mm while that of the control sides was 18.14 ± 5.37 mm. The difference in length, with a mean of 5.46 ± 3.67 mm, was highly statistically significant ($p < 0.001$) (Figure 3).

Similarly, the mean diameter of hairs from legs with cast application (83.20 ± 14.84 μ m) was significantly greater than the control sides (68.31 ± 11.69 μ m), with a mean difference of 15.28 ± 6.41 μ m ($p < 0.001$) (Figure 4).



Figure 2. Hair measurement for diameter (denoted as length in the figure).

Table I. Baseline characteristics ($n = 14$).

Age (years)	
Mean	37.21
Max	82
Min	12
Sex	
Male	7 (50%)
Female	7 (50%)
Skin type	
III	10 (71.43%)
IV	3 (21.43%)
V	1 (7.14%)
Duration (weeks)	
Mean (SD) = 6.50 (3.107)	
4	4 (28.6%)
5	1 (7.1%)
6	5 (35.7%)
8	3 (21.4%)
16	1 (7.1%)
Type of casts	
Short leg	8 (57.1%)
Long leg	5 (35.7%)
Cylinder	1 (7.1%)
Reason for cast application	
Fracture	11 (78.57%)
Soft tissue injury	3 (21.43%)
Site of injury	
Knee	3 (21.4%)
Leg	6 (42.9%)
Ankle	4 (28.6%)
Foot	1 (7.1%)

SD = standard deviation.

Linear correlation between duration of cast application and degrees of hair changes showed that the duration significantly correlated with degrees of changes in hair length ($r = 0.57$, $p = 0.035$) but not with hair diameter ($r = 0.19$, $p > 0.05$).

The authors also analyzed whether the difference of hair changes correlated with distance from injury site. Although there was an inverse relationship for both length and diameter (Pearson correlation; $r = -0.142$ for hair length, $r = -0.178$ for hair diameter), this was not statistically significant ($p > 0.05$).

On subjective assessment, 66.67% of patients had grossly visible changes for all three parameters: hair length, diameter and density on the cast side (Figure 5). Minimal changes, albeit noticeable, were observed in 55.56% and 66.67% in terms of hair length and diameter, respectively. Moderate increases (score +2)

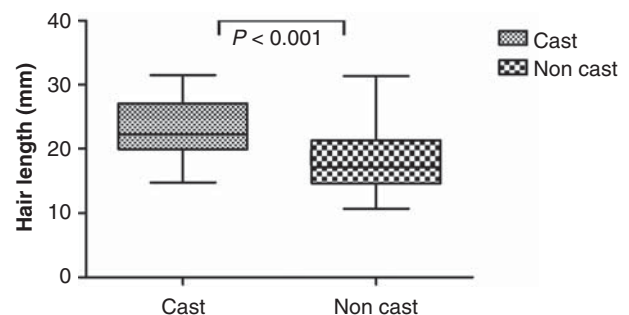


Figure 3. Mean lengths of hairs from legs with and without cast application.

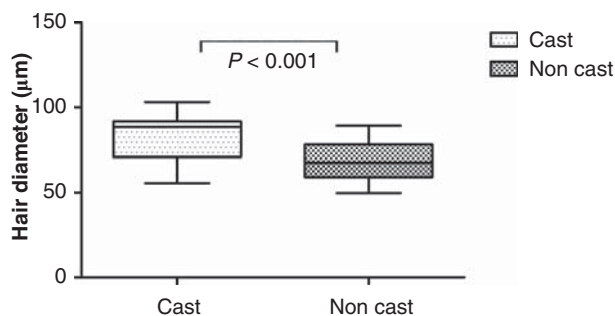


Figure 4. Mean diameters of hairs from legs with and without cast application.

were noted at 22.22%, 22.22% and 66.67% for hair length, diameter and density, respectively (Figure 6). There was only one patient who had no change in any of the three parameters. One patient had a minimal decrease in hair density on the cast side.

Discussion

Hair is one of the most complicated cutaneous structures. Its growth cycle is a complex process involving cell differentiation,

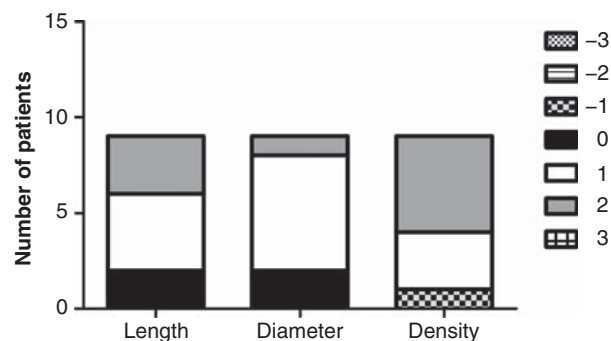


Figure 6. Evaluators' assessments of overall changes.

epithelial-mesenchymal interactions, stem cell induction, programmed cell death and pigmented cell alteration. The duration of stages in hair cycle varies dramatically in various parts of the human body resulting in different hair lengths and diameters (9). Apart from the known intrinsic stimuli, hair growth is also under the influence of several external physical factors as briefly mentioned above.

The authors demonstrated that hairs from legs with cast application, even for such short periods as 4 weeks, are significantly longer and thicker than the control side. The mean increase of more than 5 mm in length was not only statistically significant, but also grossly visible and thus clinically relevant. The fact that these highly significant changes took place after such short periods suggests that prolonged anagen phase must have taken place underneath the cast.

The mechanisms underlying cast-induced anagen prolongation are unknown. This could be due to the extrinsic factors involving injuries, cast or intrinsic factors within each patient. With soft tissue injuries, an increase in circulation and possibly angiogenesis to the injury sites can increase nutrients and oxygen supply to the hair follicles. The formation of new blood vessels is a major driving force for hair growth which is regulated, at least in part, by vascular endothelial growth factor (VEGF) (10). Studies involving histomorphometry, electron microscopy and immunohistochemistry have shown that there is a close relationship between angiogenesis and hair cycle. During the anagen phase, there is an increase in microvascular formation which regresses during catagen and telogen (11). Although there was a trend toward an inverse correlation between degrees of hair change and distances from the injury sites, this was not statistically significant. Moreover, the study clearly showed that hair growth occurs in a diffuse pattern rather than only in the vicinity of the injury.

Prolonged occlusion by cast contributes to changes of skin environment which includes heat, increased humidity and reduced transepidermal water loss. Several lines of evidence suggest that temperature change can affect hair growth. At least in mice, areas with second-degree burn that received local hyperthermia had significantly more hair follicles compared with control (12). Paradoxical hypertrichosis occurring at the periphery of intense pulsed light (IPL)-treated area could be minimized by applying cold packs to the surrounding area, suggesting that heat, and not scattering photons alone, plays important roles in this interesting phenomenon (13). Hypothermia, on the other hand, also alters hair growth cycles as seen in oncology patients whereby induction of scalp hypothermia can prevent chemotherapy-induced hair loss (14,15).

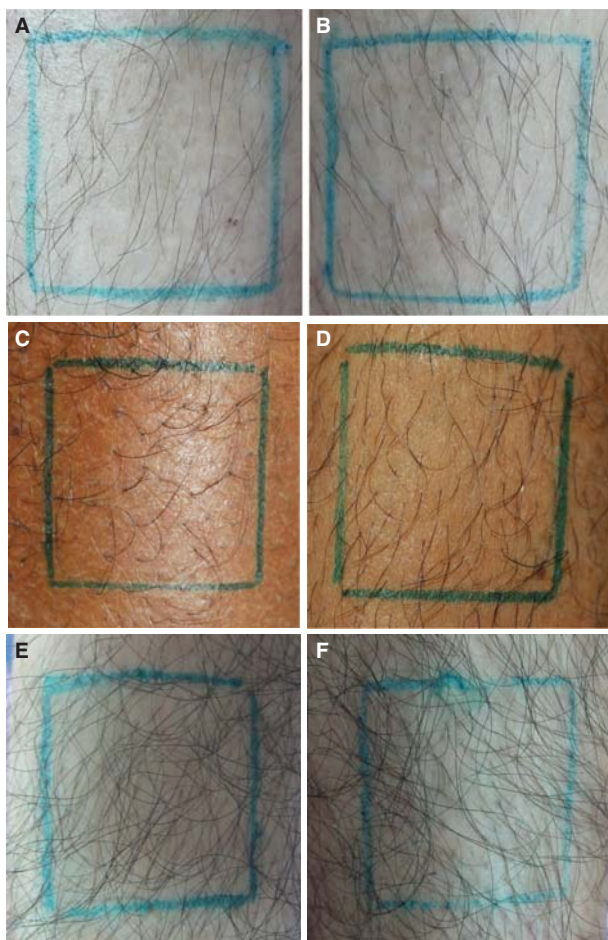


Figure 5. Three sets of macrophotographs showing clinically greater hair density on the legs where cast was applied. A 45-year-old patient, no cast (A), with cast applied for 6 weeks (B). A 37-year-old male patient, no cast (C) with long leg cast applied for 8 weeks (D). A 42-year-old male patient, no cast (E) with cast applied for 8 weeks (F).

Prolonged skin inflammation may induce changes in hair growth cycle, which result in localized hypertrichosis as seen in sack bearing, lichen simplex chronicus or habitual biting. Chronic and frequent irritation may contribute to skin inflammation and vascularization which are known factors for hair growth stimulation. Up to date, there are no data indicating whether cast materials can stimulate hair growth. Benzalkonium chloride present in plaster of Paris can cause skin inflammation but this reaction is rare and all of our patients had no signs of dermatitis. Moreover, there is evidence showing that hypertrichosis occurs not only with plaster of Paris but also with fiberglass casts.

The strengths of this study are the highly accurate and objective measurements which allowed to detect even the subtle changes in hair diameters in micrometers. The authors also demonstrated that duration of cast application correlates with the increases in lengths. Limitations are that this is a single-center, cross-sectional study with a relatively small sample size resulting in restriction of inference potentials. Additionally, there were no baseline or follow-up data of the patients.

In summary, cast application of only 4 weeks' duration can significantly stimulate hair growth. The study results may open new doors to the basic knowledge in hair biology as well as initiating new paradigms in hair management focusing on physical approach rather than medications in the future.

Acknowledgements

The authors would like to acknowledge the kind assistance of Nathaphon SaeTan, Biomedical Science Program, Faculty of Graduate School for all objective measurements, Panlop Chakavittumrong, MD of Department of Medicine, Faculty of Medicine, Thammasat Hospital, Watchai Mingbunjerdasuk, MD, Department of Corrections, Ministry of Justice and Pawinee Rerknimitr, MD of Division of Dermatology, Department of Medicine, Faculty of Medicine, Chulalongkorn University for their assistance in subjective assessments.

Declaration of interest: The authors report no conflict of interest. The authors alone are responsible for the content and writing of the paper.

References

1. Rangwala S, Rashid RM. Alopecia: a review of laser and light therapies. *Dermatol Online J.* 2012;18:3.
2. Chang CH, Cohen PR. Ipsilateral post-cast hypertrichosis and dyshidrotic dermatitis. *Arch Phys Med Rehabil.* 1995;76:97-100.
3. Kara A, Kanra G, Alanay Y. Localized acquired hypertrichosis following cast application. *Pediatr Dermatol.* 2001;18:57-59.
4. Leung AK, Kiefer GN. Localized acquired hypertrichosis associated with fracture and cast application. *J Natl Med Assoc.* 1989;81:65-67.
5. Nielsen JS. Localized hirsutism following Colles' fractures. *Can Med Assoc J.* 1983;129:229.
6. Bergen D. Localized hirsutism following Colle's fracture. *Can Med Assoc J.* 1983;128:368.
7. Pick RY. Focal hair growth under plaster-of-Paris cast. *NY State J Med.* 1980;80:1726.
8. Harper MC. Localized acquired hypertrichosis associated with fractures of the arm in young females. A report of two cases. *Orthopedics.* 1986;9:73-74.
9. Saitoh M, Uzuka M, Sakamoto M. Human hair cycle. *J Invest Dermatol.* 1970;54:65-81.
10. Semalty M, Semalty A, Joshi GP, Rawat MS. Hair growth and rejuvenation: an overview. *J Dermatol. Treat.* 22:123-132.
11. Mecklenburg L, Tobin DJ, Muller-Rover S, Handjiski B, Wendt G, Peters EM, et al. Active hair growth (anagen) is associated with angiogenesis. *J Invest Dermatol.* 2000;114:909-916.
12. Shahabi S, Hashemi M, Hassan ZM, Javan M, Bathaie SZ, Toraihi T, et al. The effect of post-burn local hyperthermia on the reducing burn injury: the possible role of opioids. *Int J Hyperthermia.* 2006;22:421-431.
13. Willey A, Torrontegui J, Azpiazu J, Landa N. Hair stimulation following laser and intense pulsed light photo-epilation: review of 543 cases and ways to manage it. *Lasers Surg Med.* 2007;39:297-301.
14. Dean JC, Salmon SE, Griffith KS. Prevention of doxorubicin-induced hair loss with scalp hypothermia. *N Engl J Med.* 1979;301:1427-1429.
15. Ridderheim M, Bjurberg M, Gustavsson A. Scalp hypothermia to prevent chemotherapy-induced alopecia is effective and safe: a pilot study of a new digitized scalp-cooling system used in 74 patients. *Support Care Cancer.* 2003;11:371-377.